Future CARDIOLOGY

Device Evaluation

Focus on STENTYS Xposition S self-apposing stent: a review of available literature

Dario Pellegrini[1] & Bernardo Cortese*,[2]
[1]Department of Medicine and Surgery, Università degli Studi di Milano-Bicocca, Milan, Italy
[2]Department of Cardiac, San Carlo Clinic, Via Leonardo da Vinci, Paderno Dugnano, Milano, Italy
*Author for correspondence: bcortese@gmail.com

Percutaneous coronary interventions are the primary revascularization strategy for the vast majority of patients with coronary artery disease. Nevertheless, challenging settings still limit optimal results, especially in case of significant tapering, bifurcations or primary angioplasty in ST-segment elevation myocardial infarction. Stentys self-apposing stent was designed to improve strut apposition to the vessel wall and to adapt to difficult targets. The Xposition S is a sirolimus-eluting stent with a novel delivery system, to improve accurate positioning. Several studies compared the device with traditional balloon-expandable stents, showing better results in terms of malapposition reduction and a noninferiority in relation to procedural outcomes. Available data show good clinical results, but a direct comparison with balloon-expandable stents from large randomized trials is still lacking. Thus, the Stentys Xposition S can be an alternative to traditional stents in dedicated scenarios, but strong evidence from large randomized trials is needed to derive stronger recommendations.

First draft submitted: 29 November 2018; Accepted for publication: 27 March 2019; Published online: 26 April 2019

Keywords: bifurcation • drug-eluting stent • left main • malapposition • self-apposing stent

Current limitations of percutaneous coronary angioplasty

From its introduction, the role of percutaneous coronary intervention (PCI) has been constantly growing, and it is nowadays the main revascularization strategy for the vast majority of patients with coronary artery disease. Accordingly, coronary stent technology has improved significantly, with major changes in materials, design and drugs. Nowadays, a wide variety of solutions exist for percutaneous revascularization. However, the debate between PCI and coronary artery bypass graft still persists, especially in specific settings where the outcome of PCI has always been suboptimal.

In particular, two elements may represent significant limitation to optimal results of stenting: significant tapering in diameter from proximal to distal segments of the target vessel, and involvement of a bifurcation in the atherosclerotic plaque, due both to significant diameter mismatch and to the need for side branch treatment.

In vessels with significant tapering, optimal stent sizing may be difficult, especially with traditional balloon-expandable stents, as these devices usually have a tubular shape that may not adapt to the significant mismatch between proximal and distal vessel diameter, and their theoretical expansion is limited to the size of the balloon they are crimped on, or the one used for postdilatation [1]. Two complications may derive from stent/vessel size mismatch. On the proximal portion of the stent, significant malapposition of the struts may occur [2], thus delaying tissue coverage and increasing the risk of stent thrombosis [3–6]. On the other hand, the distal segment may be overdilated due to stent oversizing, with the risk of dissection at the stent edge, plaque/thrombus embolization or plaque rupture [1,7].

Proximal optimization technique was developed to better fit tubular stents in tapering vessels. Results with second- and third-generation drug-eluting stents have been good, but this strategy may bear significant risks, as proximal overexpansion of the stent on the one hand could damage the vessel wall and, on the other hand, it may overdilate the cells of the device, causing a possible impairment of scaffolding properties, reduced (or nonuniform) drug elution, and prolapse of the plaque inside the cells.

Future Medicine

Left main coronary artery (LM) seems the iconic example of all these issues put together. Historically, an unprotected critical stenosis of the LM was a clear indication for coronary artery bypass graft, with strong supporting evidence [8]. The continuous improvements in percutaneous techniques and devices progressively reduced the gap in recent years [9], and finally the latest guidelines of the European Society of Cardiology on revascularization [10] addressed PCI as a feasible and effective strategy for the treatment of LM disease, in case of low and moderate SYNTAX scores (class I, level of recommendation A for low SYNTAX Score, class IIa, level of recommendation A, for intermediate score). Nevertheless, the aforementioned limitations still affect the outcomes of percutaneous procedures in this setting [11,12].

Finally, another common risk factor for stent malapposition is PCI in patients with ST-segment elevation myocardial infarction (STEMI). The presence of thrombus and epicardial vasoconstriction can cause an underestimation of the real lumen size in this setting [5,13–15], and stent undersizing is a known risk factor for late thrombosis. The reported prevalence of undersizing is 20–30% of the overall percutaneous coronary revascularizations, but it may be even higher in case of emergency PCI. On the other hand, the use of oversized balloons in thrombotic vessels increases the risk of no-reflow phenomenon. Thus, STEMI patients present specific and critical conditions that need to be addressed to ensure an optimal result of revascularization and a major impact on prognosis.

These issues triggered the interest for innovative devices that may be able to adapt to variable anatomies and different conditions. Within a wide range of different solutions, self-apposing stents presented specific advantages over traditional balloon-expandable stents. The STENTYS self-apposing stent was the main exponent of this category and was investigated in multiple studies. This review will analyze the characteristics of the device and the available evidence in challenging clinical settings.

Characteristics of the Stentys self-apposing stent

Specifics of the device

The Stentys Xposition S coronary stent is a self-apposing, sirolimus-eluting stent (1.4 μg/mm^2 of drug per surface), available in four lengths (17, 22, 27 and 37 mm) and three sizes: 2.5–3.0 mm (small), 3.0–3.5 mm (medium) and 3.5–4.5 mm (large). Originally, the first version of the DES eluted paclitaxel (paclitaxel-eluting stent [PES]), at the concentration of 0.8 μg/mm^2, but this drug was discontinued for sirolimus in 2015 (sirolimus-eluting stent [SES]).

Struts have a nominal width of 102 μm (for small size) or 133 μm (for medium and large size stents), are made out of nitinol, a nickel-titanium alloy, and are incorporated in a proprietary coating, ProTeqtor® (Hemoteq AG, Würselen, Germany), a durable polymer matrix of polysulfone and polyvinylpyrrolidone that acts as an excipient. The stent is compatible with a 6-French guiding catheter and conventional 0.014″ guidewires, on a monorail delivery system.

Thanks to the elastic and shape memory properties of nitinol, the struts appose to the vessel wall with a low, chronic outward force (Figure 1). The Chronic Outward Force exerted by the stent is relatively low (~0.1 N/mm), while the radial-resistive force (the force that the stent exhibits when resisting against compression of the vessel) is around 0.82 N/mm for the medium stent at 3.0 mm. The theoretical maximum diameter reached with the 'medium'-sized device is 5 mm, and 6.5 mm with the 'large' one, so the different sizes are compatible with a maximum vessel diameter of 4, 5 and 6 mm, respectively. Two radio-opaque markers mark the proximal and distal stent edges, for higher accuracy in deployment and postdilatation. Cell area is 0.95 mm^2, metal/artery ratio is less than 30% and free implant surface is ≥70%.

Originally, the STENTYS was launched as a bifurcation-oriented stent [16,17], as struts are organized in a Z-shaped mesh, linked by small interconnectors. This system allows for easy recross and disconnection of the struts with a balloon angioplasty (Figure 2), to provide better access to the side branch, without the need for kissing balloon [17–19].

The STENTYS stent is Conformité Européenne (CE) marked and commercially available in Europe. Lesion preparation, including thrombus aspiration and predilatation, is at the discretion of the operator. Balloon postdilatation after STENTYS placement is strongly recommended [20].

It is noteworthy that struts are significantly thicker than those of other drug-eluting stents, which nowadays range between 60 and 90 μm, and that the shortest available length is 17 mm, which could be a limitation in case of short lesions.

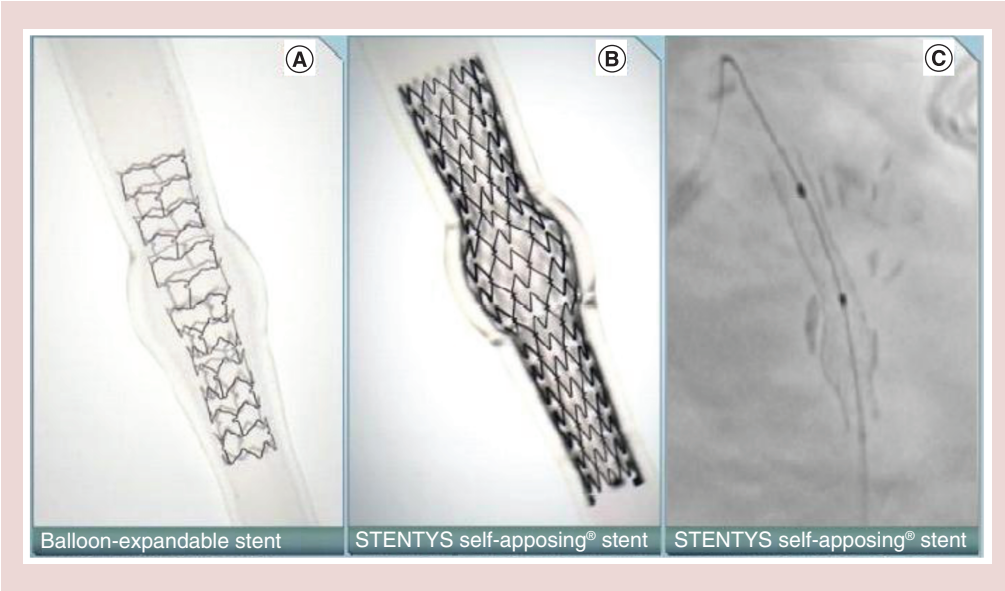

Figure 1. Results of different stents in a vessel with a significant variability in lumen diameter. Portrayed are a balloon-expandable stent **(A)**, the Stentys self-apposing stent **(B)** and a 'stent boost' image of the Stentys self-apposing stent **(C)**.
Courtesy of STENTYS®.

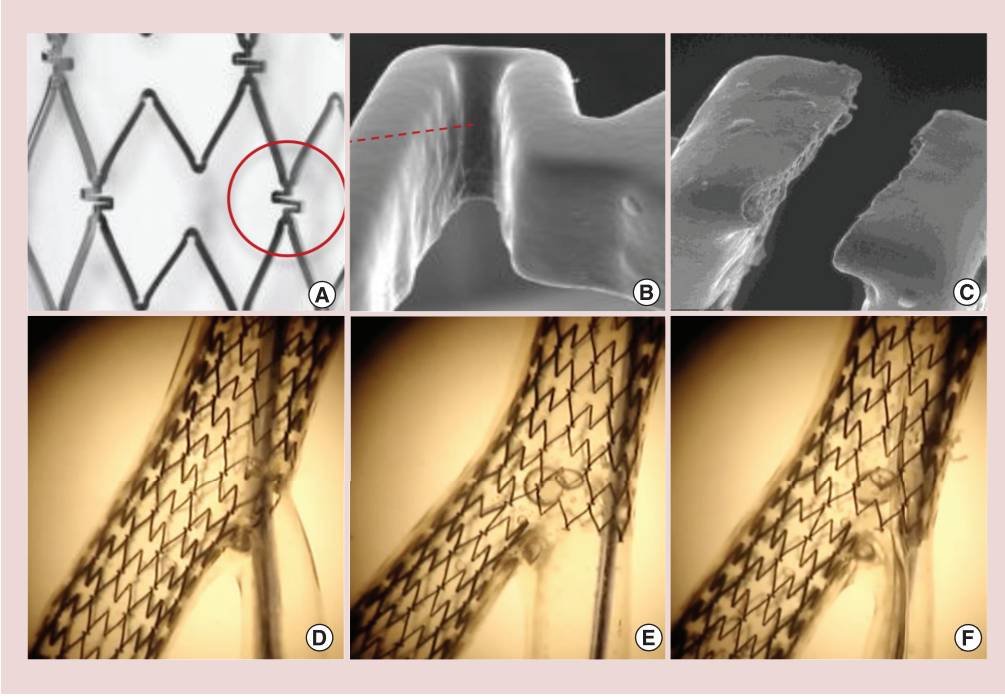

Figure 2. Treatment of bifurcation lesions with Stentys self-apposing stent. Close view of the Z mesh of the stent **(A)**, with interconnectors between struts **(A & B)**. In case of bifurcation, recross of the wire inside a cell and balloon inflation easily break the interconnectors **(C)**, thus opening the cells of the stent and allowing easy treatment of the side branch. Panels D, E and F: *in vitro* demonstration of the procedure: stent recrossing **(D)**, opening of the cells **(E)** and final result **(F)**.
Courtesy of STENTYS®.

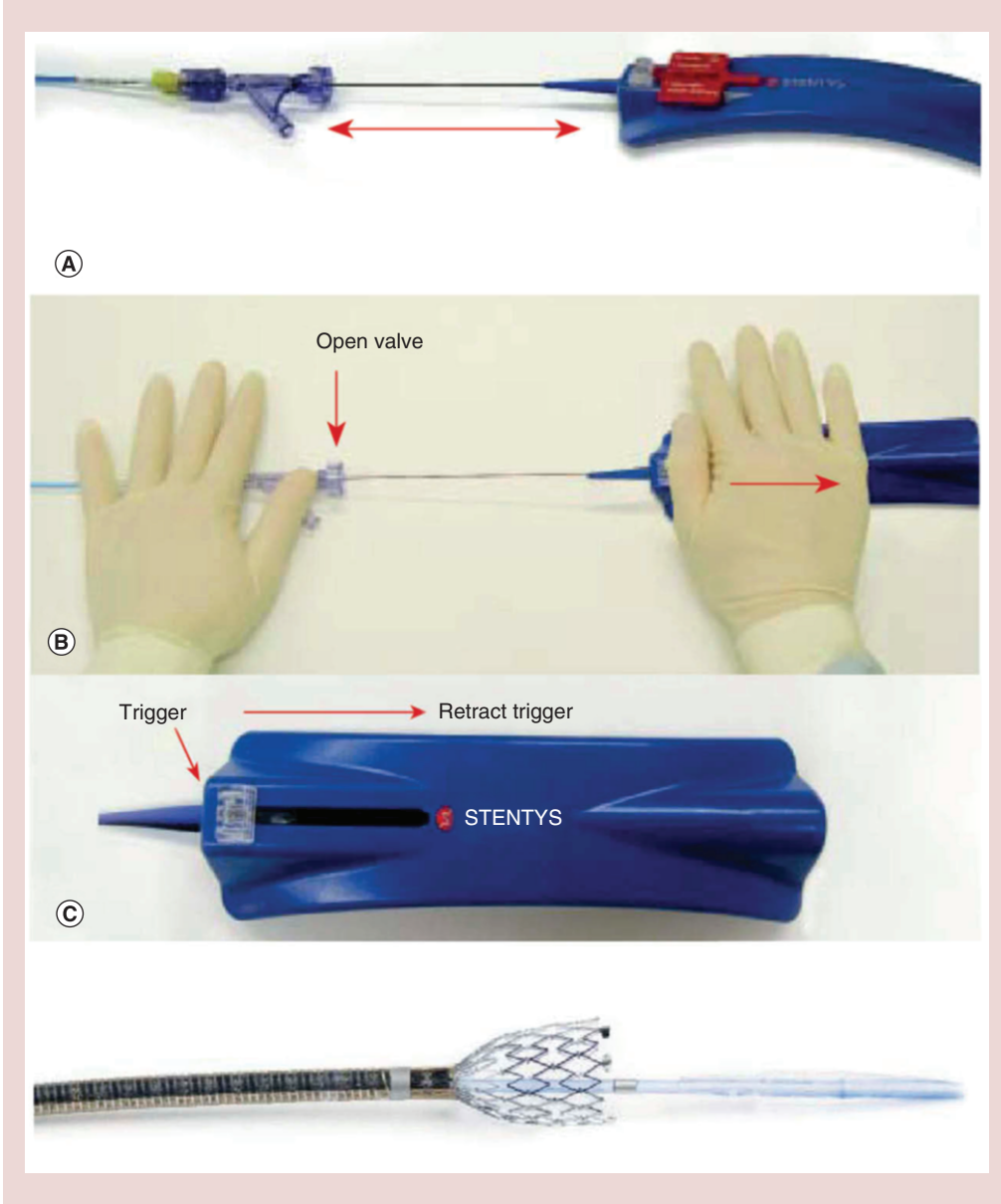

Figure 3. Conventional delivery system for the original Stentys self-apposing stent. The stent is folded inside the delivery sheath. First step is to straighten the catheter and delivery system **(A)**. Open the valve and pull back the system until the stent reaches the desired position **(B)**. Slowly retract the trigger under fluoroscopy guidance **(C)** to retract the sheath from distal to proximal end **(D)**. When the stent is completely free, remove the delivery system. Courtesy of STENTYS®.

Delivery system

In the first version, the stent was crimped inside a retractable sheath. Slow withdrawal of the sheath allowed progressive expansion of the stent, from the distal to the proximal segment (Figure 3). However, this system had some technical limitations. Indeed, when released from the delivery sheath, nitinol may suddenly release elastic energy and a 'jumping phenomenon' [21,22] may occur, resulting in a difficult placement and a high risk of geographic miss.

Therefore, a new delivery system, the Xposition S, was developed and adopted on the new version of the Stentys sirolimus DES [23]. The stent is mounted on a semicompliant balloon and covered by a 0.0032″-thick splittable sheath (Figure 4). When the balloon is inflated, it splits the external sheath from the distal to the proximal end, allowing the stent to appose to the vessel wall (thus, the aim of balloon inflation is to set the stent free of the sheath,

Figure 4. New Xposition S delivery system. The stent is crimped on a semicompliant balloon and enveloped in a splittable sheath **(A)**. Inflation of the balloon splits the sheath; the stent is free to self-expand **(B)**. Deflation of the balloon **(C)**. Retraction of the sheath and of the delivery system **(D)**. See text for further details. Courtesy of STENTYS®.

not to inflate the stent itself). The sheath is then withdrawn with the delivery balloon. The delivery system is fully 6-French compatible, while the previous system had to be deployed in 6-French guides only with one guide wire in place, thus not allowing adequate protection of side branches.

The first trial to demonstrate the efficacy of the new delivery system of the Stentys Xposition S was the SET-UP study (Study to evaluate the safety and feasibility of the STENTYS Balloon Delivery System), a prospective, single-arm first-in-man study on a population of 25 consecutive patients [23]. Primary outcomes were procedural success and longitudinal geographic miss at quantitative coronary analysis (QCA), which were 100 and 0%, respectively. Postprocedural incomplete stent apposition was 2.4 and 0.6% before and after postdilatation ($p = 0.013$). At 30 days, the major adverse cardiovascular event (MACE) rate was 4%, as a patient had a stent thrombosis due to inadequate antithrombotic treatment. Thus, the study showed an adequate performance of the new delivery system.

Despite the positive results of the study, a certain learning curve and some caution is needed during delivery system retraction. Indeed, after stent expansion, the sheath is jailed between the vessel wall and the struts and it requires significant effort to pull it back into the guide. Intense friction may damage the endothelium and even cause dissection. A recent study on 38 patients [24] found no differences in the dissection rate assessed with optical coherence tomography (OCT) between the Xposition S delivery system and the conventional delivery system of the previous version of the device, but larger trials are needed to gather stronger evidence. On the other hand, the pulling maneuvers cause the guiding catheter to advance inside the vessel, with the risk of proximal vessel dissection or even strut dislodgement, in case of proximal stenting. Thus, it is recommended to advance the guidewire in the vessel, and to retire the guide several millimeters before pulling the sheath.

Apposition (STEMI)	
I	**Feasibility trial:** Single arm – STENTYS BMS (n = 25) → 3 day and 6 month QCA and IVUS. Amoroso G, et al. assessment of the safety and performance of the STENTYS self-expanding coronary stent in acute myocardial infarction: results from the APPOSITION I study. EuroIntervention 2011; 7(4): 428–436.
II	**Randomized trial:** STENTYS BMS vs ABBOTT VISION/Medtronic Driver (n = 80) → 3 day QCA and OCT, 6 month clinical. Published in JACC Interventions. van Geuns RJ, et al. Self-expanding versus balloon-expandable stents in acute myocardial infarction: results from the APPOSITION II study: self-expanding stents in ST-segment elevation myocardial infarction. JACC Cardiovasc Interv. 2012; 5: 1209–1219.
III	**"Real life" study:** Single arm – STENTYS BMS & DES (n = 1000) → 30 day and 12, 24 month MACE. Article submitted to EuroIntervention. Koch KT, et al. One-year clinical outcomes of the STENTYS self-apposing(R) coronary stent in patients presenting with ST-segment elevation myocardial infarction: results from the APPOSITION III registry. EuroIntervention. 2015; 11: 264–271
IV	**Randomized trial:** STENTYS Sirolimus DES(s) vs Medtronic Resolute (n = 150) → 4 or 9 month OCT. Article submitted to JACC Interventions. van Geuns R-J; et al., STENTYS Self-Apposing® sirolimus-eluting stent in ST-segment elevation myocardial infarction: results from the randomized APPOSITION IV trial. EuroIntervention 2016; 11: e1267–e1274
V	**IDE - Randomized trial:** STENTYS BMS vs ABBOTT Multi-link (n = 880) → 12 month TVF, IVUS/OCT sub-study – *ENROLLMENT terminated*
Open (Bifurcation)	
I	**Feasibility trial:** Single Arm – STENTYS BMS & DES (n = 60) → 6 month QCA and IVUS. Verheye S et al. Six month clinical and angiographic results of the STENTYS® self-apposing stent in Bifurcation Lesion. EuroIntervention. 2011; 7: 580–587.
II	**"Real life" study:** Single arm – STENTYS DES (n = 200) → 6 month MACE, OCT sub-group. Naber, C. K., et al. (2015). Final results of a self-apposing paclitaxel-eluting stent for the PErcutaNeous treatment of de novo lesions in native bifurcated coronary arteries study. *EuroIntervention,* 11(2), 1–5.
Saphenous vein grafts	
ADEPT	**Randomized trial:** STENTYS BMS vs STENTYS DES (n = 80) → 6 months QCA – late loss Ijsselmuiden, A et al. (2014). Comparison between self-apposing bare metal and paclitaxel-eluting coronary stents for the treatment of saphenous vein grafts: The ADEPT study. *EuroIntervention*.
All-cormers	
SIZING	**All-comers registry:** STENTYS BMS & DES in ACS (STEMI, NSTEMI) and stable patients (bifurcation, ectatic, tapered, aneurysm, SVG) (n = 3000) ***Enrollment in progress (> 1500 pts enrolled)***
WIN	**Prospective, non-randomized multi-center study:** Xposition S in ACS and stable patients (bifurcation, ectatic, tapered, aneurysm, SVG) (n = 750) • 12 month target lesion Failure (TLF), defined as cardiac death, myocardial infarction in the stented segment, clinically driven target lesion revascularizaton (TLR) **Enrollment started Q1 2017**
Balloon deliverable system	
SETUP	First-in-man trial: STENTYS BDS SES (n = 25) → one month follow-up; CE mark data and customer feedback Lu, H, et al. (2015). First-in-man evaluation of the novel balloon delivery system STENTYS Xposition S for the self-apposing coronary artery stent: impact on longitudinal geographic miss during stenting. EuroIntervention, 11(1).
Below the knee	
BTK	**Safety and efficacy:** STENTYS PES below the knee → 6 months patency (n = 70). 12 month data available end of September.
Left main	
TRUNC	**Prospective, non-randomized multi-center study:** Xposition S is left main (n = 200) **Enrollment commenced in Q3 2016**

Figure 5. Schematic representation of the scientific program performed over the years to test the Stentys self-apposing stent.
BMS: Bare metal stents; CE: Conformité Européenne; IVUS: Intravascular ultrasound; OCT: Optical coherence tomography; PES: Paclitaxel-eluting stent; QCA: Coronary analysis.
Courtesy of STENTYS®.

Available evidence in different fields of application

The Stentys self-apposable stent has been studied in different settings, with a wide program of feasibility and postmarketing studies (Figure 5) that encompassed all the versions of the device. Here, the most important trials performed so far, and derived clinical evidence, are reported. Unfortunately, as the Xposition S platform is relatively new, most of the studies investigated the previous iteration of the device, and only a few analyzed the new delivery system. In order to provide a more comprehensive excursus on the scientific program of the device, each section will provide information on historical perspectives related to previous iterations of the device, other than data on the current version of the stent (if available).

Bifurcations

Historical perspective

The main studies dealing with the performance of the Stentys stents in *de novo* bifurcation lesions were the OPEN (STENTYS Coronary Bifurcation Stent System for the PErcutaNeous treatment of *de novo* lesions in native bifurcated coronary arteries) trials [17,25,26]. All of these trials evaluated older versions of the device.

The OPEN I trial [17] was a multicenter, prospective, single-arm study on 63 patients, with a clinical follow-up of 6 months. A total of 60 stents were deployed (33 bare metal stents [BMS], 27 PES). Poststenting strut disconnection was performed in 90% of the cases and stenting of the side branch in 30%. Procedural success (primary outcome) was achieved in 95.2% of the cases. At 6 months, MACE occurred in 3.7% of the patients treated with the Stentys DES and consisted only of target lesion revascularization (TLR), while the event rate was significantly higher in patients treated with BMS (27.3%, with TLR being 24.2%). At 6-month angiographic follow-up, late lumen loss (LLL) in case of PES was 0.42 ± 0.45 and 0.16 ± 0.45 mm in the target main vessel and side branch, respectively, while in patients treated with BMS it was 0.87 ± 0.65 and 0.54 ± 0.51 mm, respectively. Intravascular ultrasound (IVUS) evaluation detected an increase in mean stent area from baseline to follow-up, from 7.52 ± 1.86 to 12.32 ± 2.90 mm^2 ($p < 0.001$) for DES, and from 7.95 ± 1.40 to 11.56 ± 2.22 ($p < 0.001$) for BMS.

The OPEN II trial [26] was a multicenter prospective observational study that analyzed the performance of the Stentys PES, on 207 patients. The primary end point, consisting in the MACE rate at 12 months, was 13% (10.1% at 6 months). The event rate was mainly driven by TLR, while reported stent thrombosis at 12 months was 1% [25]. In 56% of the procedures, disconnection of the struts toward the side branch was performed, based on operator

decision, and final kissing-balloon in 21.7%. However, no significant differences in the MACE rate were detected between the subjects receiving final kissing-balloon and those not receiving it.

Evidence on current device

No trials evaluated the performance of the new Xposition S in the specific setting of bifurcations. The good results obtained in studies on the Stentys BMS and PES may be extendable to the current SES, as the design of the stent did not change across its different versions, and the only major change was a reduction in strut thickness. In addition, evidence available in the field of PCI of distal left main stem can provide additional data in the setting of bifurcation treatment.

STEMI & primary angioplasty

The safety and efficacy of the STENTYS stent in the setting of STEMI and primary angioplasty was evaluated in a series of studies grouped under the APPOSITION (Assessment of the Safety and Performance of the STENTYS self-expanding Coronary Stent in Acute Myocardial Infarction) program, which analyzed all versions of the stent across the years.

Historical perspective

The APPOSITION I was the first prospective, multicenter, nonrandomized trial that evaluated the performance of the device (BMS) in 25 patients with STEMI, with IVUS or OCT evaluation at the end of the procedure, at 3 days and at 6 months [27]. There were no MACE at the 6-month follow-up (primary end point). Technical success (i.e., correct delivery of stent) was achieved in 100% of patients, while procedural success (i.e., technical success with residual stenosis <20% and TIMI III flow) was achieved in 96%. At 6 months, in-stent and in-segment LLL were 0.71 ± 0.71 and 0.58 ± 0.61 mm, respectively. Binary restenosis was 25% and ischemia-driven TLR 12%. IVUS and OCT assessment 3 days after the procedure showed an increase in minimum lumen area of 19% ($p < 0.001$). Incomplete stent apposition at 3 days was detected in one patient; however, at 6 months there were no incomplete appositions.

These results were tested in the following APPOSITION II trial, a randomized study that compared the Stentys BMS and a balloon-expandable BMS in 80 STEMI patients [28]. The primary outcome was the percentage of malapposed struts assessed by OCT at 3 days, which was significantly lower in the Stentys group (0.58 vs 5.46% of control patients, respectively; $p < 0.001$), with 0% of the patients having more than 5% of malapposed struts, compared with 26% in the control group ($p < 0.001$). There were no differences in the secondary end point (6-month rate of MACE: 2.3 vs 0% in Stentys and control group, respectively; p: NS). However, the trial lacked sufficient statistical power for clinical events. In the OCT substudy [29], incomplete stent apposition was significantly lower in the Stentys group than in control group, both in case of persistent malapposition (11.5 vs 14.8%, $p < 0.01$) and in case of newly acquired malapposition (2.7 vs 14.8%, $p < 0.01$). This difference was found to be driven by a mix of tissue resorption, vasorelaxation and early recoil in the balloon-expandable stent group, while in the Stentys group only tissue resorption played a significant role.

The APPOSITION III (a postmarket registry to assess the Stentys self-exPanding COronary Stent In AcuTe MyocardIal InfarctiON) registry aimed at analyzing clinical events with the adequate statistical power that its predecessor lacked. This study was a prospective, multicenter, postmarket registry that evaluated both the Stentys BMS and PES [30,31]. 956 patients were followed-up for 2 years. A prespecified safety interim analysis after the enrollment of the first 400 patients showed that postdilatation of the stent provided a significant reduction in MACE rates, therefore, postdilatation was strongly recommended for the remaining cohort. At 2 years, the global rate of MACE was 11.2%, with stent thrombosis incidence being 3.3% (with a 0.5% increase from first to second year of follow-up) [20]. Postdilatation allowed a significant reduction in TLR and stent thrombosis rates at 30 days, as definite stent thrombosis was 2.2% in postdilatation group and 5.3% in no postdilatation group, respectively ($p = 0.01$). From 30 days to 2 years, the stent thrombosis rate was 0.6 and 1.2%, respectively (nonsignificant difference). Thus, this result supported the hypothesis that the low, chronic outward force of nitinol would prevent chronic malapposition, but it would still require postdilatation after implantation to prevent acute malapposition.

Finally, the APPOSITION V [32], a multicenter, prospective, single-blinded, randomized trial, compared the Stentys BMS with a standard balloon-expandable BMS. The primary end point was target vessel failure (TVF) at 12 months. The initial plan was to enroll 880 patients, but it stopped at 303 patients due to slow enrollment [Unpublished Data] [33]. At 12 months follow-up, the noninferiority outcome was not met, due to a higher rate

of TVF in the Stentys group (12 vs 7.1%; p for noninferiority = 0.33). Moreover, stent thrombosis rates were significantly higher in the STENTYS group (6.2 vs 1%, p = 0.04), mainly in the early phase (<24 h after the procedure). The investigators-related stent thrombosis rate to a lack of postdilatation of the stent, which was not performed in a high number of cases, leading probably to a higher incidence of acutely malapposed or uncovered struts.

Evidence on current device

The Stentys Xposition S in the STEMI setting was studied with the APPOSITION IV trial (randomized comparison between the Stentys Self-Apposing Sirolimus-eluting coronary stent and a balloon-expandable stent in acute myocardial infarction). This prospective, multicenter trial randomized 152 patients either to the sirolimus Stentys or a zotarolimus-eluting balloon expandable stent [34]. OCT re-evaluation was performed at 4 or at 9 months. At 4 months, the Stentys had a significant lower percentage of malapposed and uncovered struts compared with the control group (0.07 vs. 1.16%, respectively; p = 0.002). However, at 9 months there were no differences between the groups (0.43 vs 0.28%, respectively; p = 0.55). There were no significant differences in the MACE rate, even though the study was underpowered for hard clinical events.

Saphenous vein grafts

Due to their large lumen diameter, frequent caliber changes and thrombus burden, saphenous vein grafts are theoretically good candidates for PCI with this device. To date, there are no specific data on the performance of the Xposition S stent. The BMS and PES versions of the device were compared in the multicenter randomized ADEPT trial [35], on 57 patients. LLL at 6 months (primary end point) was similar in both groups (0.53 vs 0.47 mm, respectively; p = 0.86). Secondary end points were procedural success (89.5% overall, 92.6% for BMS, 86.7% for PES; p = 0.67) and the MACE rate at 12 months (22.2% in BMS and 26.7% in DES, p = 0.70). Thus, no differences were found in terms of LLL and adverse cardiovascular events between the BMS and paclitaxel-eluting version of the stent in the setting of PCI of saphenous vein grafts.

Left main stem

As previously stated, lesions of the left main seem a good target for Stentys stent, due to the usually large diameter, the tapering characteristics and the presence of a major bifurcation when the disease involves the distal portion.

Historical perspective

The first study to evaluate the outcomes of this self-apposable stent was a single-center, pilot registry in Poland, on 24 patients [19]. The results suggested that Stentys PES was a feasible and effective alternative to treat body and distal LM disease, with a high rate of acute procedural success (95.8%) and no adverse events during hospitalization and 30 days follow-up.

The following year, a multicenter study [36], evaluated the performance in a larger population (75 patients), compared with second-generation DES. Final balloon diameters at the QCA were significantly larger in the control group (4.51 ± 0.51 vs 3.62 ± 0.49 mm; p < 0.001), but the IVUS evaluation revealed a significantly larger final minimal lumen area in the Stentys group. MACE rates were similar at 12 months follow-up.

Evidence on current device

The first experience with the new Stentys Xposition S, in the treatment of LM, came from a small study on 20 consecutive patients presenting with coronary artery disease involving the LM and acute coronary syndrome [37]. Mean age was 73.9 ± 10.1 years, 90% of the patients presented with NSTEMI and 10% with STEMI. Technical success was achieved in 95% of cases and angiographic success (defined as final lesion <20% and TIMI 3 flow) in 80% of subjects. There were no cases of geographical miss, in support of the new delivery system, and no early stent-related complications up to 30 days follow-up.

The following year, the MATISSE (Main Angioplasty with a Self-apposing Stent) study [38], a spontaneous retrospective, multicenter international registry, evaluated the outcomes of the Stentys DES in 151 patients, over a mean follow-up time of 348 ± 52 days. Procedural success was achieved in 150 subjects and the primary outcome (DOCE, a composite of cardiac death, TLR and target-vessel myocardial infarction) occurred in ten patients (6.9%), with TLR rate being 4.6% and stent thrombosis 1.2% (Figure 6). Results were similar to those of the

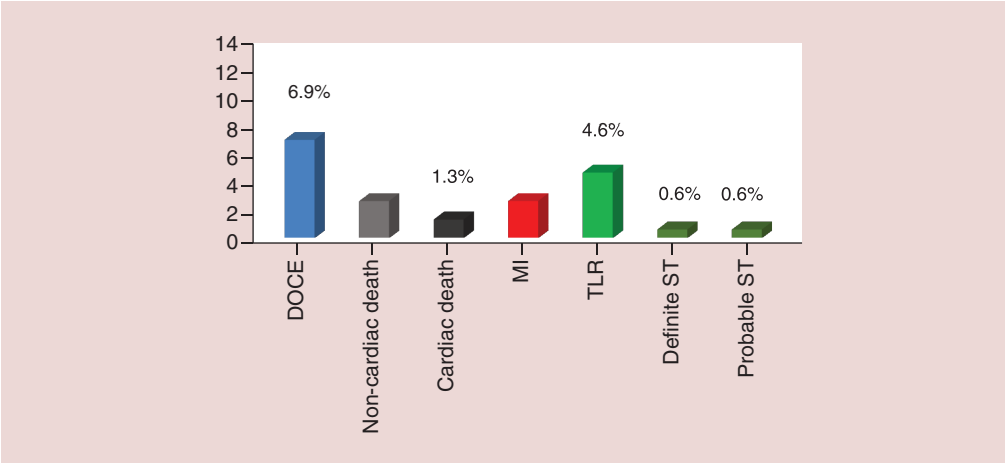

Figure 6. Clinical outcome of the MATISSE study.
TLR: Target lesion revascularization.
Graphical elaboration of data taken from [38].

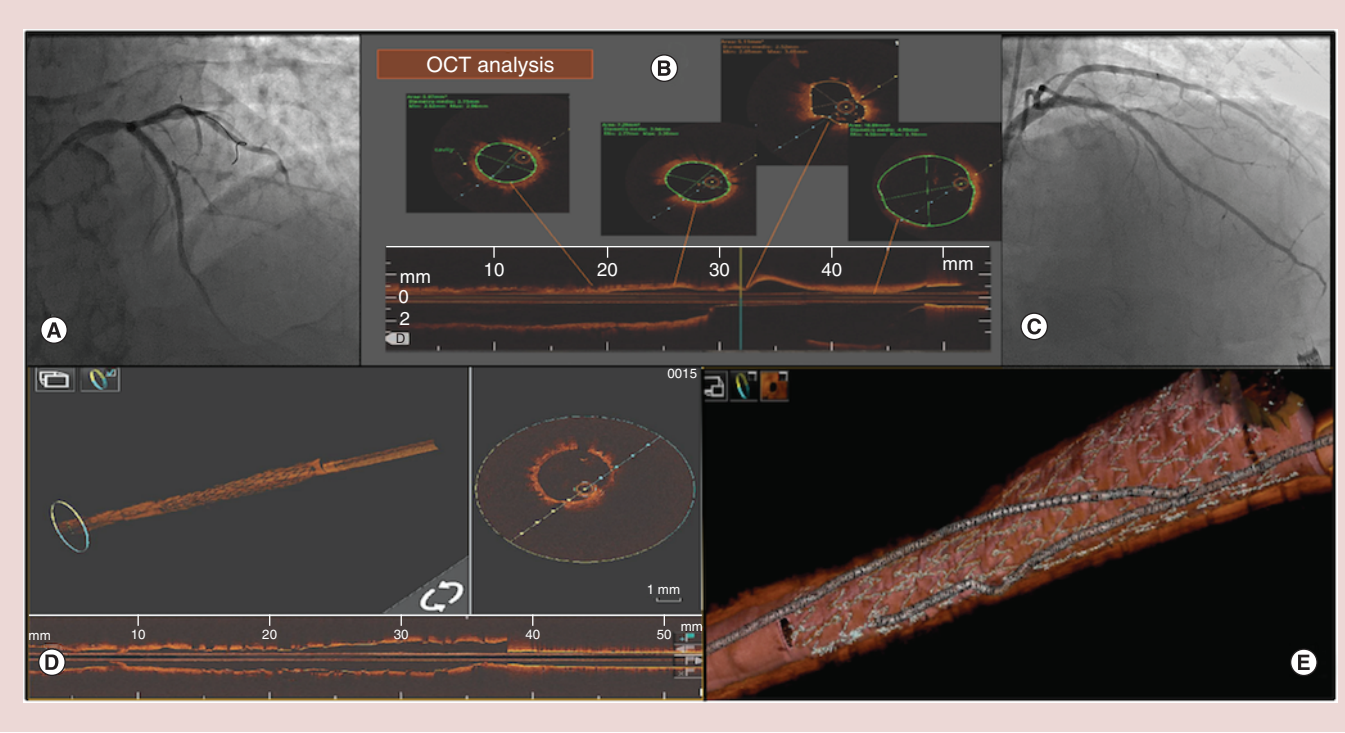

Figure 7. Angiography and internal optical coherence tomographic reconstruction of a patient treated with Stentys DES for distal left main disease.
OCT: Optical coherence tomography.
Adapted with permission from [38].

major studies on the current generation of balloon-expandable DES, like the EXCEL [39], PRECOMBAT [40] and ISAR-LEFT MAIN II [41] trials (Figures 7 & 8).

An angiographic substudy was performed on 33 patients. At a median scheduled angiographic follow-up of 7.8 ± 3.7 months, QCA analysis showed a negative LLL in the left main of -0.1 ± 0.9 mm (baseline reference vessel diameter 4.1 ± 0.5 mm, final diameter 3.8 ± 0.6 mm). LLL of left anterior descending and circumflex

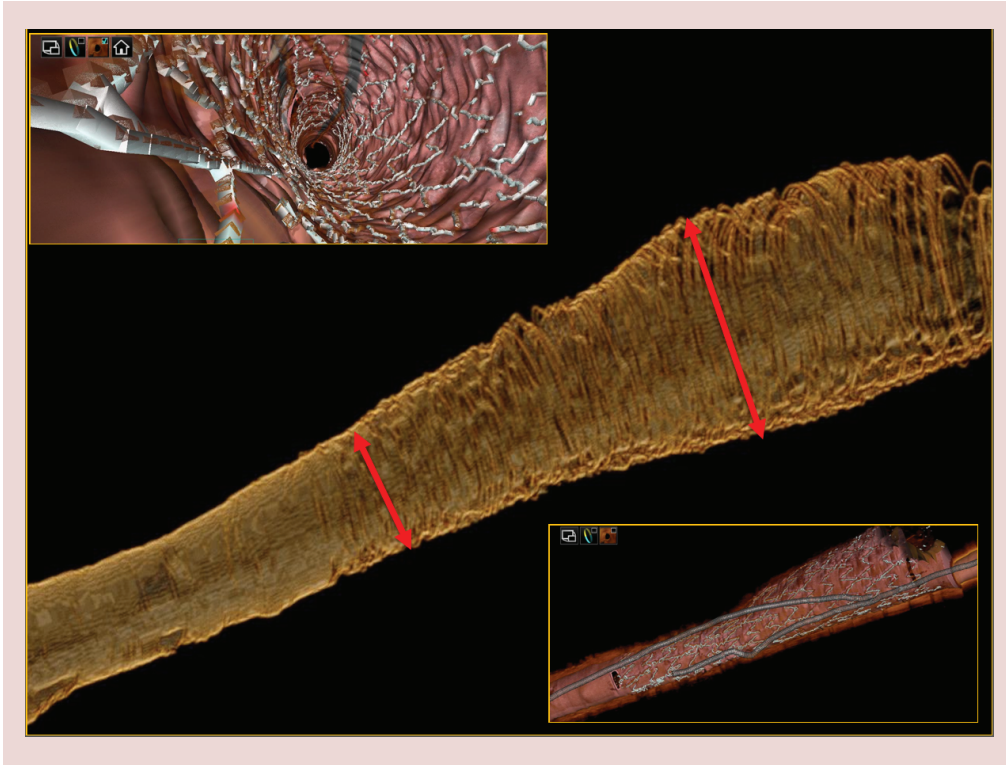

Figure 8. External optical coherence tomographic reconstruction of a patient treated with Stentys DES for distal left main disease, showing the adaptability of this device to tapered vessels.
Adapted with permission from [38].

arteries were, respectively, 0.3 ± 0.3 (baseline RVD 3.2 ± 0.4 mm, final result 3 ± 0.5 mm) and 0.3 ± 0.4 mm (baseline RVD 2.8 ± 0.5 mm, final result 2.8 ± 0.5 mm).

Recently, the TRUNC study (Multicenter Prospective Clinical Study of the Stentys Xposition S for Treatment of Unprotected Left Main Coronary Artery Disease) evaluated the safety and efficacy of the Stentys Xposition S in the setting of unprotected LM PCI. This was a prospective, single-arm, multicenter registry on 205 patients. Preliminary results were presented at the 2018 Transcatheter Cardiovascular Therapeutics-TCT meeting (presenter C Tamburino) [42]. Angiographic success (primary efficacy end point) was achieved in 96.6% of the patients. Primary clinical end point consisted of target lesion failure (a composite of cardiac death, MI not attributable to a nontarget vessel and clinically driven TLR) at 12 months (8.3%), mainly driven by TLR (5.4%), which occurred at the untreated side branch ostium in 7 out of 11 cases. These results were comparable to the existing data on LM treatment with traditional balloon-expandable DES. Stent thrombosis occurred in 0.5% of the patients. Interestingly, the rate of radial artery approach was relatively low (59%), despite being the preferred one in most centers. Moreover, bifurcation was treated with simple plain old balloon angioplasty of the side branch in 53.8% of the cases, with stent implantation being performed only in 20.6%. Postdilatation of the stent was performed in 83.9% of the cases. IVUS substudy on 50 subjects showed that 98% of the stents had no malapposed struts. Complete results from the trial with the official publication will provide more data on the performance of the Stentys Xposition S in this challenging setting.

Registries & postmarketing surveillance

Evidence on the efficacy and safety of the different versions of the Stentys stents are available from registries, gathering data from real-world, unselected patients, in a wide variety of anatomical and clinical scenarios.

Historical perspective

A real-world registry from Italy [21] evaluated 109 patients in different clinical settings, with either BMS or paclitaxel version of the Stentys. 54% of patients presented with STEMI, 29.4% with NSTEMI, 16.5% with stable coronary

artery disease. Mean follow-up was 23.6 ± 12.6 months. MACE occurred in 5.5% of the cases, with stent thrombosis occurring in 1.8%. Another small Italian real-world registry [43] on 40 patients with the Stentys BMS showed an acute thrombosis rate of 2.5% and a MACE rate of 10% at 21 ± 13 months follow-up.

One of the longest available follow-ups, at 5 years, in a population of 120 individuals (101 DES and 19 BMS) showed a TVF of 24% (DES 22.8% vs BMS 33%, p = 0.26). Definite stent thrombosis rate was 3.8% [44].

Evidence on current device

Gaede *et al.* retrospectively evaluated a population of 314 consecutive patients treated with the device, with a total of 351 stents (including Stentys BMS, paclitaxel and sirolimus eluting stents, even though the exact number of each type of DES was not known) [45]. Mean age was 70 years and acute coronary syndrome was the presenting condition in 42% of the patients. Technical success was achieved in 94% of cases. Noteworthy, it was much lower than the reported 99% rates of concomitant studies [31]. Procedural failure rate was 6%, due to the impossibility of a correct positioning of the device. A possible explanation of these suboptimal results could be found in the old version of the delivery system employed, which was affected by the aforementioned deliverability issues. Mean clinical follow-up was 2.5 years. Primary outcome was target lesion failure (a composite of cardiac death, target vessel-related MI, clinically driven TLR) and occurred in 18% of the patients, being significantly higher than the results of the available balloon-expandable stents [46–48]. Stent thrombosis rate was 2.6% (1.5% after 30 days, 2.2% after 6 months). This rate was higher than DES, too, as it is classically reported to be below 1%. Moreover, postdilatation was not associated with a net benefit.

At the moment, there are two ongoing large, the SIZING study and the WIN (Worldwide registry to assess the Stentys Xposition S for revascularization of coronary arteries In routine cliNical practice) registry. The SIZING study is a worldwide registry that is aiming to enroll 3000 patients with a stent sizing dilemma and different clinical presentations, treated either with Stentys BMS, PES or SES. Coprimary end points are procedural success and MACE at discharge and at 12 months. An interim analysis was presented at TCT meeting in 2017 [49]. 588 patients treated with the new Stentys Xposition S had a MACE rate of 5.1% at 12 months, with cardiac death occurring in 1.6%, target vessel-MI in 2.1% and clinically driven TLR in 3.1%. Stent thrombosis occurred in 0.75% at 12 months. Thus, preliminary data suggest that the new version of the stent, coupled with the new delivery system, provides good results both in terms of efficacy and safety. Complete results of the SIZING and WIN studies are awaited.

Regulatory affairs

The Stentys Xposition S stent received CE mark and is currently available in Europe, Middle East, eastern Asia, Latin and South America. At the time of writing, the device is not available in the USA and is not approved by the US FDA. Reimbursement policies vary according to different nations; however, conditions similar to balloon-expandable stents usually apply.

Final remarks

Self-apposing stents present numerous theoretical advantages that may help improve the outcomes of PCI, especially in challenging settings, like bifurcations, vessels with a significant tapering and revascularization during STEMI. Different imaging modalities (from traditional coronary angiography to more advanced techniques, like IVUS and OCT) have detected a significant improvement in strut apposition to the vessel wall, compared with traditional balloon-expandable stents. Nevertheless, yet these benefits did not produce a clear, significant improvement in 'hard' clinical outcomes, like cardiac mortality, target vessel-MI or TLR.

An important topic to be underlined is the somewhat technical challenge for the use of this device and the required physiological learning curve, which can be modulated by a specific training [50]. Indeed, this device has different properties compared with conventional stents, and the operator needs to get used to the elastic properties of nitinol, as suggested by the 'jumping phenomenon' observed in the previous versions of the stent. Even with the new Xposition S, there is a theoretical risk of damage to the vessel wall, even though no significant evidence supports this hypothesis.

On the other hand, controlled and randomized trials showed good results in the hands of skilled operators. There is a significant risk of amplification of negative results in registries, due to a larger proportion of PCI performed by operators with insufficient experience with the device. An adequate run-in period may prevent this issue in future studies, but the quantification of its impact in available trials is extremely difficult.

10.2217/fca-2018-0087

Finally, there are still some controversies regarding the postdilatation of this device. Theoretically, there would be no need for balloon postdilatation in self-apposing stents, due to their active expansion against the radial resistance of the vessel wall over time. However, balloon postdilatation was associated with improved clinical outcome in randomized controlled trials [20,31], especially in bifurcations and OCT studies confirmed the findings [23]. In particular, the APPOSITION III trial [20] showed a significant drop in adverse events after the systematic application of a standardized implantation protocol (predilatation – implantation – postdilatation).

Available data support the hypothesis that gentle postdilatation is needed to prevent early complications, probably because the stent itself lacks sufficient radial strength to achieve adequate expansion in stenotic, often calcified, lesions, especially if the predilatation was not completely effective. Therefore, postdilatation would prevent incomplete expansion of the stent, which might result in stent eccentricity and in an increased risk of stent thrombosis [51].

These data could explain the higher incidence of stent thrombosis emerged from some nonrandomized studies and registries. Indeed, several adverse events were recorded in patients which did not have adequate pre- or postdilatation of the stent [45]. Moreover, the nonrandomized and often retrospective nature of these studies, the simultaneous involvement of different versions of the stent in single registries, along with centers with uncertain experience (as previously stated, the learning curve phenomenon may play a significant role) add a significant risk of bias. These factors limit speculations on possible higher thrombogenicity of the stent itself. The available, reassuring data from robust trials, like the APPOSITION program, should be considered as reference, until new results from dedicated trials and registries on the Xposition S (like the WIN and SIZING registries), which follow a specific procedural protocol, become available. Noteworthy, preliminary results of the SIZING registry showed low rates of stent thrombosis at 12 months [49].

Conclusion

In conclusion, the self-apposing Stentys stent is an effective and safe alternative to traditional balloon-expandable stents, especially in challenging settings. The new Xposition S represents a major evolution of the device compared with the previous versions. However, more data are needed to better assess the outcomes of this self-apposing stent compared with traditional devices and provide clear recommendations to operators.

Executive summary

- Percutaneous coronary intervention is the major revascularization strategy in the vast majority of patients with coronary artery disease, but challenging lesions limit the outcome, in particular in case of vessels with a significant variation of their lumen diameter over their length (i.e., significant tapering, bifurcations) or over time (i.e., ST-segment elevation myocardial infarction).
- Self-apposing stents improve strut apposition to the vessel wall by exerting a chronic, outward force due to their materials and design. The Stentys self-apposing stent is the main exponent of this category.
- The stent was at first available as a bare metal stents and a paclitaxel-eluting stent. Previous versions were discontinued in favor of the new Xposition S sirolimus-eluting stent.
- Correct delivery of the self-apposing stent is a critical step. The conventional delivery system available with the previous version of the Stentys self-apposing stent had major drawbacks in terms of risk for geographic miss. The new Xposition S delivery system allows for a precise positioning, while limiting the risk for complications. Nevertheless, great caution is required during deployment.
- Postdilatation of this stent is always recommended, to improve strut apposition and reduce acute complications.
- A wide program of trials addressed the different scenarios of usage of the device: bifurcations, ST-segment elevation myocardial infarction, left main. Postmarketing surveillance continues with large, prospective, observational studies (SIZING and WIN registries).
- Available studies confirmed better results of the device in terms of strut apposition to the vessel wall compared with traditional balloon-expandable stents, along with good clinical outcomes. Nevertheless, strong evidence on a direct comparison with traditional stents in relation to clinical performance is still missing.

Financial & competing interests disclosure

The authors have no relevant affiliations or financial involvement with any organization or entity with a financial interest in or financial conflict with the subject matter or materials discussed in the manuscript. This includes employment, consultancies, honoraria, stock ownership or options, expert testimony, grants or patents received or pending, or royalties.

No writing assistance was utilized in the production of this manuscript.

References

Papers of special note have been highlighted as: • of interest

1. Foin N, Alegria E, Sen S *et al.* Importance of knowing stent design threshold diameters and post-dilatation capacities to optimise stent selection and prevent stent overexpansion/incomplete apposition during PCI [letter]. *Int. J. Cardiol.* 166(3), 755–758 (2013).
2. Cook S, Wenaweser P, Togni M *et al.* Incomplete stent apposition and very late stent thrombosis after drug-eluting stent implantation. *Circulation* 115, 2426–2434 (2007).
3. Gutiérrez-Chico JL, Regar E, Nüesch E *et al.* Delayed coverage in malapposed and side-branch struts with respect to well-apposed struts in drug-eluting stents: *in vivo* assessment with optical coherence tomography. *Circulation* 124, 612–623 (2011).
4. Cook S, Ladich E, Nakazawa G *et al.* Correlation of intravascular ultrasound findings with histopathological analysis of thrombus aspirates in patients with very late drug-eluting stent thrombosis. *Circulation* 120, 391–399 (2009).
5. Nakano M, Yahagi K, Otsuka F *et al.* Causes of early stent thrombosis in patients presenting with acute coronary syndrome: an *ex vivo* human autopsy study. *J. Am. Coll. Cardiol.* 63, 2510–2520 (2014).
6. Gomez-Lara J, Radu M, Brugaletta S *et al.* Serial analysis of the malapposed and uncovered struts of the new generation of everolimus-eluting bioresorbable scaffold with optical coherence tomography. *JACC Cardiovasc. Interv.* 4, 992–1001 (2011).
7. Ahn JM, Lee PH, Park SJ. Practical based approach to left main bifurcation stenting. *BMC Cardiovasc. Disord.* 16, 49 (2016).
8. Yusuf S, Zucker D, Peduzzi P *et al.* Effect of coronary artery bypass graft surgery on survival: overview of 10-year results from randomised trials by the Coronary Artery Bypass Graft Surgery Trialists Collaboration. *Lancet* 344, 563–570 (1994).
9. Stone GW, Sabik JF, Serruys PW *et al.* Everolimus-eluting stents or bypass surgery for left main coronary artery disease. *N. Engl. J. Med.* 375, 2223–2235 (2016).
10. Neumann FJ, Sousa-Uva M, Ahlsson A *et al.* 2018 ESC/EACTS Guidelines on myocardial revascularization. *Eur. Heart J.* 40, 87–165 (2019).
11. Biondi-Zoccai GG, Lotrionte M, Moretti C *et al.* A collaborative systematic review and meta-analysis on 1278 patients undergoing percutaneous drug-eluting stenting for unprotected left main coronary artery disease. *Am. Heart J.* 155, 274–283 (2008).
12. Teirstein PS. Unprotected left main intervention: patient selection, operator technique, and clinical outcomes. *JACC Cardiovasc. Interv.* 1, 5–13 (2008).
13. Cheneau E, Leborgne L, Mintz GS *et al.* Predictors of subacute stent thrombosis: results of a systematic intravascular ultrasound study. *Circulation* 108, 43–47 (2003).
14. Kim YS, Koo BK, Seo JB *et al.* The incidence and predictors of postprocedural incomplete stent apposition after angiographically successful drug-eluting stent implantation. *Catheter. Cardiovasc. Interv.* 74, 58–63 (2009).
15. van Werkum JW, Heestermans AA, Zomer AC *et al.* Predictors of coronary stent thrombosis: the Dutch Stent Thrombosis Registry. *J. Am. Coll. Cardiol.* 53, 1399–1409 (2009).
16. Laborde JC, Borenstein N, Behr L, Ramcharitar S. Stentys coronary bifurcation stent. *EuroIntervention* 3, 162–165 (2007).
17. Verheye S, Grube E, Ramcharitar S *et al.* First-in-man (FIM) study of the Stentys bifurcation stent–30 days results. *EuroIntervention* 4, 566–571 (2009).
18. Ramcharitar S, Verheye S. The STENTYS® self-apposing stent in bifurcation lesions. *EuroIntervention* 6(Suppl. J), J151–J154 (2010).
19. Smolka G, Wańha W, Roleder T, Pluta A, Ochała A. Treatment of left main coronary artery stenosis with the STENTYS self-expandable drug-eluting stent – a pilot registry. *Postepy Kardiol. Interwencyjnej.* 10, 226–230 (2014).
20. Lu H, Grundeken MJ, Vos NS *et al.* Clinical outcomes with the STENTYS self-apposing coronary stent in patients presenting with ST-segment elevation myocardial infarction: two-year insights from the APPOSITION III (A Post-Market registry to assess the STENTYS self-exPanding COronary Stent In AcuTe MyocardIal InfarctiON) registry. *EuroIntervention* 13, e572–e577 (2017).

• **Showed the significant benefit deriving from postdilatation of the stent on major adverse cardiovascular events.**

21. Silenzi S, Grossi P, Mariani L, Aimi A, Marchese P, Moretti L. A real world single centre experience using the STENTYS self-expanding coronary stent [letter]. *Int. J. Cardiol.* 209, 57–59 (2016).
22. Giordano A, Corcione N, Polimeno M, Messina S, Biondi-Zoccai G, Ferraro P. No surprising forward jump when deploying a self-expandable stent: two cases exploiting the combination of Emboshield Nav6 BareWire and Stentys devices. *Int. J. Cardiol.* 168, 3079–3081 (2013).
23. Lu H, IJsselmuiden AJ, Grundeken MJ *et al.* First-in-man evaluation of the novel balloon delivery system STENTYS Xposition S for the self-apposing coronary artery stent: impact on longitudinal geographic miss during stenting. *EuroIntervention* 11, 1341–1345 (2016).

• **First study to evaluate the new Xposition S Stentys stent.**

24. Lu H, Kalkman DN, Grundeken MJ *et al.* Does the novel delivery system for the STENTYS self-apposing coronary stent increase the risk of stent edge dissections? Optical coherence tomography post stent findings. *Expert. Rev. Med. Devices* 15, 157–165 (2018).

• **Optical coherence tomography (OCT)study evaluating the risk of edge dissection with the device.**

25. Naber CK, Pyxaras SA, Nef H *et al.* Final results of a self-apposing paclitaxel-eluting stent fOr the PErcutaNeous treatment of de novo lesions in native bifurcated coronary arteries study. *EuroIntervention* 12, 356–358 (2016).

26. Verheye S, Ramcharitar S, Grube E *et al.* Six-month clinical and angiographic results of the STENTYS® self-apposing stent in bifurcation lesions. *EuroIntervention* 7, 580–587 (2011).

27. Amoroso G, van Geuns RJ, Spaulding C *et al.* Assessment of the safety and performance of the STENTYS self-expanding coronary stent in acute myocardial infarction: results from the APPOSITION I study. *EuroIntervention* 7, 428–436 (2011).

28. van Geuns RJ, Tamburino C, Fajadet J *et al.* Self-expanding versus balloon-expandable stents in acute myocardial infarction: results from the APPOSITION II study: self-expanding stents in ST-segment elevation myocardial infarction. *JACC Cardiovasc. Interv.* 5, 1209–1219 (2012).

29. Nakatani S, Onuma Y, Ishibashi Y *et al.* Incidence and potential mechanism of resolved, persistent and newly acquired malapposition three days after implantation of self-expanding or balloon-expandable stents in a STEMI population: insights from optical coherence tomography in the APPOSITION II study. *EuroIntervention* 11, 885–894 (2015).

30. Grundeken MJ, Lu H, Vos N *et al.* One-year clinical outcomes of patients presenting with ST-segment elevation myocardial infarction caused by bifurcation culprit lesions treated with the Stentys self-apposing coronary stent: results from the APPOSITION III study. *J. Invasive Cardiol.* 29, 253–258 (2017).

31. Koch KT, Grundeken MJ, Vos NS *et al.* One-year clinical outcomes of the STENTYS Self-Apposing" coronary stent in patients presenting with ST-segment elevation myocardial infarction: results from the APPOSITION III registry. *EuroIntervention* 11, 264–271 (2015).

32. Grundeken MJ, Lu H, Mehran R *et al.* APPOSITION V: STENTYS coronary stent system clinical trial in subjects with ST-segment elevation myocardial infarction – rationale and design. *Am. Heart J.* 168, 652–660 (2014).

33. Mehran R. APPOSITION V – STENTYS coronary stent system clinical trial in subjects with ST elevation myocardial infarction. *SCAI Scientific Sessions*, Orlando FL, USA (2016).

34. van Geuns RJ, Yetgin T, La Manna A *et al.* STENTYS self-apposing sirolimus-eluting stent in ST-segment elevation myocardial infarction: results from the randomised APPOSITION IV trial. *EuroIntervention* 11, e1267–e1274 (2016).

- **Large study on the Xposition S stent in the setting of ST-segment elevation myocardial infarction.**

35. IJsselmuiden AJJ, Simsek C, van Driel AG *et al.* Comparison between the STENTYS self-apposing bare metal and paclitaxel-eluting coronary stents for the treatment of saphenous vein grafts (ADEPT trial). *Neth. Heart J.* 26, 94–101 (2018).

36. Briguori C, Visconti G, Donahue M *et al.* The STENTYS® paclitaxel-eluting stent in the treatment of unprotected distal left main. *Catheter. Cardiovasc. Interv.* 86, E131–E139 (2015).

37. Kumar N, Kandan SR, Rahbi H *et al.* Single-centre experience of STENTYS Xposition S in treatment of left main stem lesions. *Expert Rev. Med. Devices.* 14, 577–582 (2017).

38. Cortese B, Montefusco A, D'Ascenzo F *et al.* Clinical performance of a dedicated self-apposing stent for the treatment of left main stem disease. Results of the left main angioplasTy wIth a self-apposing StEnt – the MATISSE study. *Cardiovasc. Revasc. Med.* 19, 831–836 (2018).

39. Serruys PW, Cavalcante R, Collet C *et al.* Outcomes after coronary stenting or bypass surgery for men and women with unprotected left main disease: the EXCEL trial. *JACC Cardiovasc. Interv.* 11, 1234–1243 (2018).

40. Seung KB, Park DW, Kim YH *et al.* Stents versus coronary-artery bypass grafting for left main coronary artery disease. *N. Engl. J. Med.* 358, 1781–1792 (2008).

41. Mehilli J, Richardt G, Valgimigli M *et al.* Zotarolimus- versus everolimus-eluting stents for unprotected left main coronary artery disease. *J. Am. Coll. Cardiol.* 62, 2075–2082 (2013).

42. Tamburino C, Briguori C, Jessurun GA *et al.* TCT-329 prospective evaluation of drug eluting self apposing stent for the treatment of unprotected left main coronary artery disease: 1-year results of the TRUNC study. *J. Am. Coll. Cardiol.* 72, B134–B135 (2018).

- **Largest study available on the Xposition S for the treatment of left main stem.**

43. Pastormerlo LE, Ciardetti M, Coceani M *et al.* Self-expanding stent for complex percutaneous coronary interventions: a real life experience. *Cardiovasc. Revasc. Med.* 17, 186–189 (2016).

44. Lu H, Bekker RJ, Grundeken MJ *et al.* Five-year clinical follow-up of the STENTYS self-apposing stent in complex coronary anatomy: a single-centre experience with report of specific angiographic indications. *Neth Heart J.* 26, 263–271 (2018).

45. Gaede L, Liebetrau C, Dörr O *et al.* Long-term clinical outcome after implantation of the self-expandable STENTYS stent in a large, multicenter cohort. *Coron. Artery Dis.* 28, 588–596 (2017).

46. Capodanno D, Gori T, Nef H *et al.* Percutaneous coronary intervention with everolimus-eluting bioresorbable vascular scaffolds in routine clinical practice: early and midterm outcomes from the European multicentre GHOST-EU registry. *EuroIntervention* 10, 1144–1153 (2015).

47. Saia F, Piovaccari G, Manari A *et al.* Clinical outcomes for sirolimus-eluting stents and polymer-coated paclitaxel-eluting stents in daily practice: results from a large multicenter registry. *J. Am. Coll. Cardiol.* 48, 1312–1318 (2006).

48. Simonton CA, Brodie B, Cheek B *et al.* Comparative clinical outcomes of paclitaxel- and sirolimus-eluting stents: results from a large prospective multicenter registry – STENT Group. *J. Am. Coll. Cardiol.* 50, 1214–1222 (2007).

49. Kauer F, Siry M, Weilenmann D *et al.* TCT-749 Worldwide every-day practice registry assessing the Xposition S Self-Apposing stent in challenging lesions with vessel diameter variance (SIZING registry). *J. Am. Coll. Cardiol.* 70, B317 (2017).

- **1-year data from the largest available registry on the Xposition S.**

50. Lu H, De Winter RJ, Koch KT. The STENTYS self-apposing stent technology in coronary artery disease: literature review and future directions. *Expert Rev. Med. Devices* 15, 479–487 (2018).

51. Sato T, Kameyama T, Noto T, Nozawa T, Inoue H. Impact of preinterventional plaque composition and eccentricity on late-acquired incomplete stent apposition after sirolimus-eluting stent implantation: an intravascular ultrasound radiofrequency analysis. *Coron. Artery Dis.* 23, 432–437 (2012).